

# CHANGES IN THE MORPHOLOGICAL PARAMETERS OF THE STOMACH MUCOSA IN WHITE MALE RATS DURING POLYPHARMASY

Toshmamatov Bakhtiyor Norbekovich

PhD, Associate Professor

Djumanova Nargiza Eshmamatovna

Senior Lecturer, Samarkand State Medical University,  
Samarkand, Uzbekistan

## Abstract

Anti-inflammatory drugs are one of the main tools for the treatment of acute and chronic pain in a wide range of diseases and pathological conditions. The use of anti-inflammatory drugs is an integral part of the practice of therapists, rheumatologists, neurologists, anesthesiologists, surgeons, traumatologists, gynecologists, etc.

**Keywords:** stomach, stomach wall, mucous membrane, polypharmacy, lymph, tissue.

## Introduction

According to the scientific literature, the organs of the digestive system are inextricably linked with the external environment. Therefore, the mucous membrane of the organs of the digestive tract is affected by food. These effects occur in constant contact with the lymphoid tissue of the gastric mucosa and the subcutaneous base, which is the immune system [11, 12]. Relevance studies in recent years have shown that 35% of the population suffers from gastritis and peptic ulcer disease. The study of organ-induced changes in the factors affecting the morphology of the gastric mucosa has been accelerating in recent years [20]. Inflammation and destructive damage to the mucous membrane of the gastrointestinal tract, which occurs against the background of taking nonsteroidal anti-inflammatory drugs, occupies one of the leading positions in medical practice. Long-term dry and solid nutrition has been shown to cause stable deviations in the morphogenetic structure of the gastric mucosa [13,19]. In recent years, as a result of various exposures to harmful factors has led to changes in the chemical and physical properties of the gastric mucosa and morphological instability of the composition of the gastric mucosa [10,23]. The problem of treating these diseases is a clear example of the complexity of managing mainly comorbid conditions. If we refer to the results of any clinical trials, the presence of comorbidity is often the exception criterion [14,21]. Some sources provide an acceptable definition of polypragmasia - the prescribing of more drugs (5 or more) than the clinical condition and quantitative determination - which is called polypragmass. In medical dictionaries, polypragmaa is also referred to as a "single prescription" kit. Most often, this phenomenon is observed in elderly patients [8,9]. Side effects of these groups of drugs are naturally associated primarily with damage to the mucous membrane of the gastrointestinal tract and the urinary system [2,3]. The data presented show that currently the fight against polypragmass with anti-inflammatory drugs is one of the important tasks of





medical care for patients of any age. Thus, damage to the gastric mucosa resulting from long-term use of nonsteroidal anti-inflammatory drugs also leads to the development of lifethreatening conditions and a decrease in adaptive response [15,16,17]. This highlights the need to develop a strategy for the effective and safe use of drugs in the treatment of patients that improves the quality of care and reduces unwanted drug reactions [22,24,25]. The gastrointestinal tract is the most complex system of interpretation and interaction of the digestive organs. They are all inextricably linked. Disruption of a single body can lead to failure of the entire system. They all perform their functions and ensure the normal functioning of the body. All parts of the fracture are interrelated and pathological processes affect one of the sections [1,4,7]. However, due to the dynamics of structural changes of the gastric mucosa, the specific features of certain etiological factors can be considered as a typical pathological process (chronic inflammation) in a number of professions [5,6]. From the above, it is clear that the work done on studies of polypragmass and its effects on the gastrointestinal tract is insufficient. There are some inconsistencies between the available data, which require further morphological and morphometric investigations. The purpose of the study: The study of various effects of harmful factors lead to a change in the chemical, physical properties of the gastric mucosa and morphological instability of the composition of the gastric mucosa. Materials and methods The experiment was performed in vivarium conditions in a total of 114 white non-breeding rats. Attention was paid to these storage conditions of rats at room temperature, in natural light and in ventilated, separate cages. In the early stages of the scientific experiments, all sexually mature rats were quarantined for seven days and transferred to the normal vivariate regimen after denial of somatic or infectious diseases. During the experiment, the physiological condition and behavior of the rats in the control group and the comparison group were carefully monitored. The following anti-inflammatory drugs were used to study the effect of polyfragmas in experimental groups of animals: Aspirin (NYaQD - salicylic acid derivatives), Paracetamol (NYaQD - anilide derivatives), Ibuprofen (NYaQD - propionic acid derivatives), Dexamethasone (synthetic antiinflammatory) effective anti-malarial agent).

### Result and Discussion

No significant change in body weight was observed in experimental rats compared with control group I, ie control animals, during the 150-day period of administration of nonspecific anti-inflammatory drugs (NAS) in different variants. Group III decreased by 3.8%, group IV by 6.1%, and our group V by 8.5% (Figure-1)



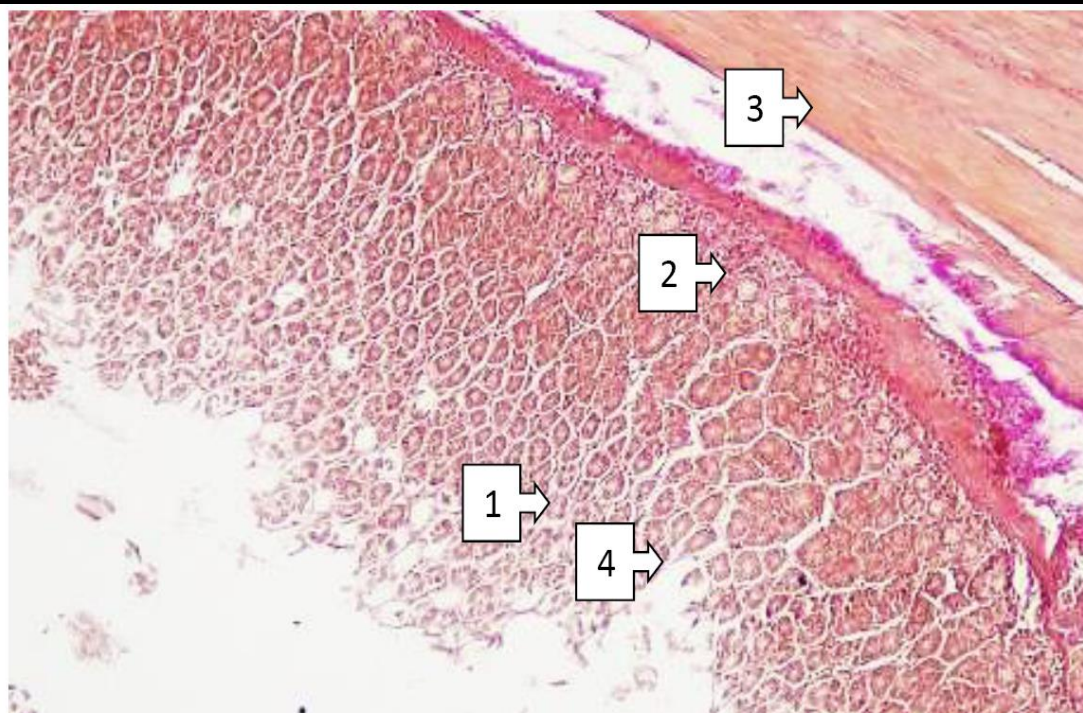


Figure 1. Cardiac section of V-white rat stomach. 1- mucosal layer, 2- submucosa base, 3- muscle layer, 4- indentation between folds. Paint Van – Gizon. Size. 10X20.

The experiments revealed the homogeneity of the gastric mucosa layer, mucosal base and large and small curves of the stomach, and the best informative indicators were the total thickness of the gastric wall, mucosal layer thickness, mucosal base thickness, folds height, glandular tissue height, pit height between folds. The accuracy of the results and the degree of their recovery were found to depend on the intake of nonsteroidal anti-inflammatory drugs by laboratory animals. The morphometric parameters of the gastric wall of 5-month-old white rats in the experiment were as follows: the total thickness of the gastric wall increased from -671.8 microns to -814.5 microns in the cardiac part, on average -  $738.6 \pm 15.41$  microns; from -786.9 microns in the pyloric part -973 , Up to 1  $\mu\text{m}$ , averaging -  $832.4 \pm 20.11$   $\mu\text{m}$ . The thickness of the mucous layer in the cardiac part ranged from -434.3  $\mu\text{m}$  to -512.1  $\mu\text{m}$ , with an average of -  $458.4 \pm 8.40$   $\mu\text{m}$ ; in the pyloric region - 373.4  $\mu\text{m}$  to -489.2  $\mu\text{m}$ , with an average of -  $443.4 \pm 12.51$   $\mu\text{m}$ . The thickness of the submucosal base ranged from -39.6  $\mu\text{m}$  to -45.79  $\mu\text{m}$  in the cardiac region, averaging -  $41.3 \pm 0.66$   $\mu\text{m}$ ; in the pyloric region from -39.1 microns to -51.9 microns, with an average of -  $46.8 \pm 1.38$  microns. The height of the glandular tissue located in the mucous layer ranged from -19.2  $\mu\text{m}$  to -27.4  $\mu\text{m}$  in the cardiac region, averaging -  $23.4 \pm 0.89$   $\mu\text{m}$ ; in the pyloric region -18.9  $\mu\text{m}$  to -24.1  $\mu\text{m}$ , with an average of -  $20.3 \pm 0.56$   $\mu\text{m}$ . When rats reach 5 months of age, the cardiac compartment contains glands containing  $19.2 \pm 0.4$  head cells. In this case, the number of stem cells in the glands of the pyloric duct is  $21.4 \pm 0.7$ , parietal cells -  $15.1 \pm 0.6$  (Figure 2). Parietal gland cells in the neck and neck area are characterized by the presence of  $21.1 \pm 0.5$  in the cardiac part, pyloric duct glandular cells -  $16.7 \pm 0.5$ , mucus-producing glandular cells -  $14.7 \pm 0.6$ .



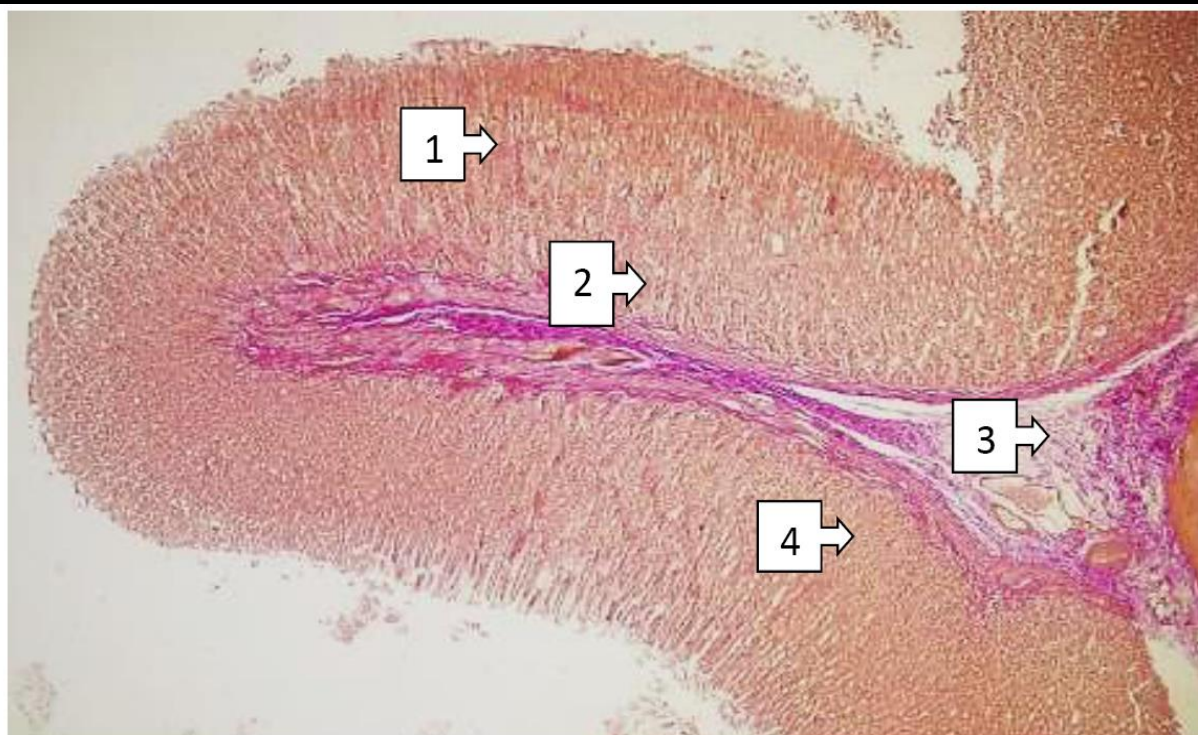

Figure 2. The structure of the stomach wall (body part) of 5-month-old rats. 1 - mucous membrane, 2 - submucosal base, 3 - muscular layer, 4 - glandular tissue of the mucous base. Stained with hematoxylin-eosin. Ok.10xob.4,0.

The body weight of 5-month-old white non-white rats under the influence of polypragmass ranged from -162 g to 241 g. to an average of  $218.8 \pm 8.22$  gni. The gastric length of the 5-month-old rats in the experiment ranged from -34 mm to 35 mm. to, average  $-34.32 \pm 0.22$  mm. The width of the stomach ranged from -13 mm to -15 mm, with an average of  $-13.81 \pm 0.22$  mm.

The thickness of the organ ranged from -12 mm to -13 mm and averaged  $-12.43 \pm 0.22$  mm. The length of the large curve ranged from -36 mm to -37 mm, with an average of  $-36.36 \pm 0.11$  mm. The length of the small curve ranged from -13 mm to -14 mm, with an average of  $-13.45 \pm 0.11$  mm. During this period, the total thickness of the gastric wall in the cardiac part of laboratory rats increased from -664.2  $\mu$ m to -758.1  $\mu$ m, on average - 719.8  $\pm 10.14$   $\mu$ m, and in the pyloric part - from -728.4  $\mu$ m to -856.3  $\mu$ m, on average - 786.3  $\pm 13.81$  microns.

Components of the tomach wall	Cardiac section (mkm)	depth (mkm)	body (mkm)	Pyloric section (mkm)
The total thickness of the stomach wall	648,5-814,3 739,8 $\pm$ 17,91	667,5- 845,3 779,2 $\pm$ 14,6 1	688,3- 857,5 786,4 $\pm$ 11,0 1	775,8-986,4 853,7 $\pm$ 22,74
The thickness of the mucous membrane	426,9-532,5 478,7 $\pm$ 11,40	436,9- 582,5 498,7 $\pm$ 12,4 1	421,9- 554,5 495,7 $\pm$ 15,0 7	365,2-498,5 439,1 $\pm$ 14,40
The height of the fold	406,5-501,3 438,9 $\pm$ 10,23	396,5- 485,2 441,9 $\pm$ 9,28	401,5- 515,4 447,9 $\pm$ 12,2 1	373,6-451,9 421,6 $\pm$ 8,46
Cloth tissue	19,0-26,3 23,8 $\pm$ 0,79	18,0-27,3 21,9 $\pm$ 0,34	19,8-24,3 22,1 $\pm$ 0,52	18,3-25,4 21,6 $\pm$ 0,77
The base of the mucous membrane	32,3-40,9 35,8 $\pm$ 0,93	31,1-39,9 34,8 $\pm$ 0,53	32,9-42,2 37,7 $\pm$ 0,82	38,8-53,7 46,8 $\pm$ 1,61



Morphological and morphometric studies confirmed the visually determined patterns: the total wall thickness, fold height, mucosal layer, mucosal base, and glandular tissue height measurements in the 5-month experimental animals were 12.72%, 8.15%, and 18, respectively, 37%, e, group 4 experimental rats decreased by 4.62%, 4.55% and 10.19%, group 3 animals decreased by 3.91%, 2.21% and 4.17% of the experiment, 2 In experimental rats, it was noted that the 1st group of the experiment was the same size as the experimental animals

### Conclusion

Thus, the results obtained showed that when we inject different amounts of drugs into the body, there are different levels of morphological and morphometric changes in their effects on tissues and cells. The effects of anti-inflammatory drugs on gastric wall elements in white non-white rats have been studied experimentally. When more than three types of anti-inflammatory drugs were used, it was found that their effect was significantly reduced in the size of the mucous layer of the gastric wall, the base of the mucosa.

### REFERENCES

1. Toshmamatov B.N. CHANGES IN MORPHOLOGICAL PARAMETERS OF THE STOMACH MUCOSA AND THE BASICS OF THE MUCOUS IMAGE OF THE STOMACH OF WHITE RATS UNDER POLYPRAGM // Proceedings of the international conference on scientific research in the field of natural and social sciences. – 2024. – T. 3. – No. 5. – pp. 162-171.
2. Toshmamatov B. N., Dzhumanova N. E. YALLIGLANISHGA KARSHI DORI VOSITALARI BILAN POLYPRAGMAZYADA MEDA DEVELOPMENT MORPHOLOGIK VA MORPHOMETRIC PARAMETRLARIDAGI OZGARISHLARI //TADQIQOTLAR. UZ. – 2024. – T. 38. – No. 1. – pp. 248-257.
3. Tashmamatov B.N., Dzhumanova N.E., Murodullaeva B.K. ECOLOGICAL GROUPING OF PLANT PHYTONEMATODES //American Journal of Educational and Pedagogical Research. – 2023. – T. 17. – P. 54-60.
4. Toshmatov B.N. Morphological Changes in the Stomach Mucosa When Using Anti-Inflammatory Drugs //Central Asian Journal of Medical and Natural Science. – 2021. – T. 2. – No. 2. – pp. 214-221.
5. Toshmamatov B. Morphological characteristics of morphometric parameters help support the stomach during polypharmacy with anti-inflammatory drugs // Catalog of dissertations and abstracts. – 2023. – T. 1. – No. 1. – P. 3-119.
6. Toshmamatov B.N., Sh.J.T., Khudoiberdiev D.K. Morphological characteristics of morphometric indicators of the gastric mucosa during polypharmacy against the background of the use of anti-inflammatory drugs. – 2022.
7. Toshmamatov B. N. CHANGES IN THE MORPHOLOGICAL PARAMETERS OF THE GASTRIC MUCOSA AND THE BASE OF THE GASTRIC MUCOSA OF WHITE RATS IN POLYPRAGMA //Proceedings of International Conference on Scientific Research in Natural and Social Sciences. – 2024. – T. 3. – No. 5. – pp. 162-171.