

TREATMENT OF POST-COVID HERPETIC NEURALGIA OF THE TRIGEMAL NERVE

Rashidova N. O.

Boyburieva R. K.

Bukhara Zarmed University

Abstract

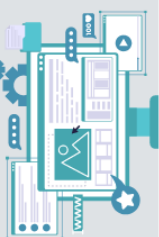The intensity and suddenness of pain syndrome, as well as the recurring nature of its attacks, lead to physical psychological exhaustion and provide grounds to consider trigeminal neuralgia as one of the most difficult diseases to endure.

Introduction

The intensity and suddenness of pain syndrome, as well as the recurring nature of its attacks, lead to physical psychological exhaustion and provide grounds to consider trigeminal neuralgia as one of the most difficult diseases to endure. In March 2020, the World Health Organization announced the beginning of the pandemic of the new coronavirus infection (COVID-19), which continues to this day. As the epidemic progressed, caused by new strains of the SARS-CoV-2 coronavirus, information was systematized regarding the disease and its relatively long-term consequences (secondary complications). The infection caused by SARS-CoV-2 (COVID-19) is accompanied by multisystem lesions of various organs and systems of the human body and often leads to fatal outcomes, especially in the presence of risk factors (old age, abdominal obesity, severe arterial hypertension, diabetes mellitus). Neurologists and infectious disease frequently involves lesions of various parts of the of the peripheral nervous system, leading to exacerbation and acute courses of various parts of the peripheral nervous system, leading to exacerbation and acute courses of herpetic infections. Although COVID-19 primarily manifests with respiratory symptoms, skin manifestations have also been described in patients with weakened immunity. It is known that COVID-19 primarily manifests with respiratory symptoms, skin manifests with respiratory symptoms, skin manifestations have also been described in patients with COVID-19. These include acroischemia, blistering eruptions, vesicles, papules, and erythematous maculopapular rashes. Herpes zoster (HZ) is caused by the varicella-zoster virus. HZ occurs in patients with weakened immunity. It is known that COVID-19 affects the immune system and can trigger HZ: many studies confirm the link between HZ and COVID-19.

In the literature, there are reports that SARA-CoV-2 may be a risk factor for the reactivation of Herpesviridae.”Reactivation of varicella-zoster virus and herpes simplex after COVID-19 vaccination: review of case reports”

“Reactivation of varicella-zoster virus and herpes simplex after COVID-19 vaccination: review of 40 cases in the international dermatological registry.”



Aim

TO study the clinical features of post-COVID herpetic neuralgia of the trigeminal nerve and to develop a treatment scheme.

Objectives

To study the complications of COVID-19 on the peripheral nervous system and to develop a treatment scheme.

Materials and Methods

Under our observation were 23 patients with trigeminal neuralgia involving branches I, II, and III of the trigeminal nerve. Among them, 16 patients had recurrent cases and 7 were primary. The age of the patients ranged from 40 to 70 years. All patients, in addition to typical neuralgia symptoms, had herpetic skin eruptions along the path of the trigeminal nerve.

MRI and electromyography studies of the trigeminal nerve branches were performed.

MRI results showed that all patients had moderate manifestations of vascular encephalopathy. Indirect signs indicated intracranial hypertension. Neurovascular conflict was detected in the trigeminal nerve area on the affected side.

Along with traditional treatment methods, patients were prescribed the antiviral cream “Herpes-Stop”(manufacturer not specified).

In the conclusions of electromyography, signs of afferent irritation and slowing of conduction along the trigeminal nerve on the afferent irritation and slowing of conduction along the trigeminal nerve on the affected side were revealed.

Alongside traditional treatment methods, an antiviral drug – Herpes-Stop cream (Manufacturer: Livzon (Group) Pharmaceutical Factory, China) – was prescribed. Its active ingredient is penciclovir.

Penciclovir acts as a blocker of viral DNA synthesis. In cells infected by the virus, it is activated and transformed into penciclovir triphosphate, which disrupts viral DNA synthesis. Unlike acyclovir, this drug is more effective in later stages of herpes, creates higher intracellular concentrations, and has a prolonged intracellular half-life (7-20 hours).

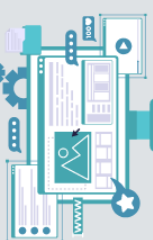Pain assessment was performed using the McGill PAIN Questionnaire (MPQ). The questionnaire includes three scales:

- Sensory scale (perception of pain),
- Affective scale (emotional impact of pain), and
- Evaluative scale (assessment of pain intensity).

The first scale consists of 13 sections containing 52 verbal pain descriptors. The second scale has 6 sections with 16 word-descriptors. The third scale corresponds to 20 characteristics and includes 5 descriptors.

In each section (subscale), the descriptors are arranged in increasing order of intensity of the evaluated characteristic.

The examined patient should select descriptors that best correspond to their sensations (only one from each section, though choosing one from every section is not mandatory).



Three indicators are analyzed:

Number of chosen descriptors index (NCDI) – total number of selected verbal characteristics.

Pain rating index (PRI) – the sum of rank numbers of the chosen descriptors in each section.

The intensity of pain is determined using the same method as in the verbal description scale.

NCDI and PRI indicators can be evaluated for the entire questionnaire or separately for each scale.

роснику или отдельно по каждой шкале.

Таблица 1.1
Краткая форма опросника о характере боли по Мак-Гиллу

№	Характеристика боли	Нет	Слабая	Умеренная	Сильная	Ужасная	Мучительная
1	Пульсирующая	0	1	2	3	4	5
2	Стреляющая	0	1	2	3	4	5
3	Колющая	0	1	2	3	4	5
4	Резкая	0	1	2	3	4	5
5	Схваткообразная	0	1	2	3	4	5
6	Грызущая	0	1	2	3	4	5
7	Жгучая	0	1	2	3	4	5
8	Ноющая	0	1	2	3	4	5
9	Мучительная	0	1	2	3	4	5
10	При касании	0	1	2	3	4	5
11	Раскалывающаяся	0	1	2	3	4	5
12	Утомительная	0	1	2	3	4	5
13	Тошнотворная	0	1	2	3	4	5
14	Пугающая	0	1	2	3	4	5
15	Жестокая	0	1	2	3	4	5

Treatment was initiated from the first appearance of rash symptoms. All patients applied Herpes-Stop cream to the affected area of the face every two hours. The therapy course lasted 4-5 days.

To strengthen the immune system, Polyoxidonium was prescribed at a dosage of 6 mg intramuscularly, every other day for 5 doses, and then twice a week (a total course of 10 injections).

We divided patients with trigeminal neuralgia (TN) into 2 groups:

Group 1 – 8 patients (34.8%) received traditional treatment for neuralgia.

Group 2 – 15 patients (65.2%) received traditional treatment supplemented with the “Herpes-Stop” cream.

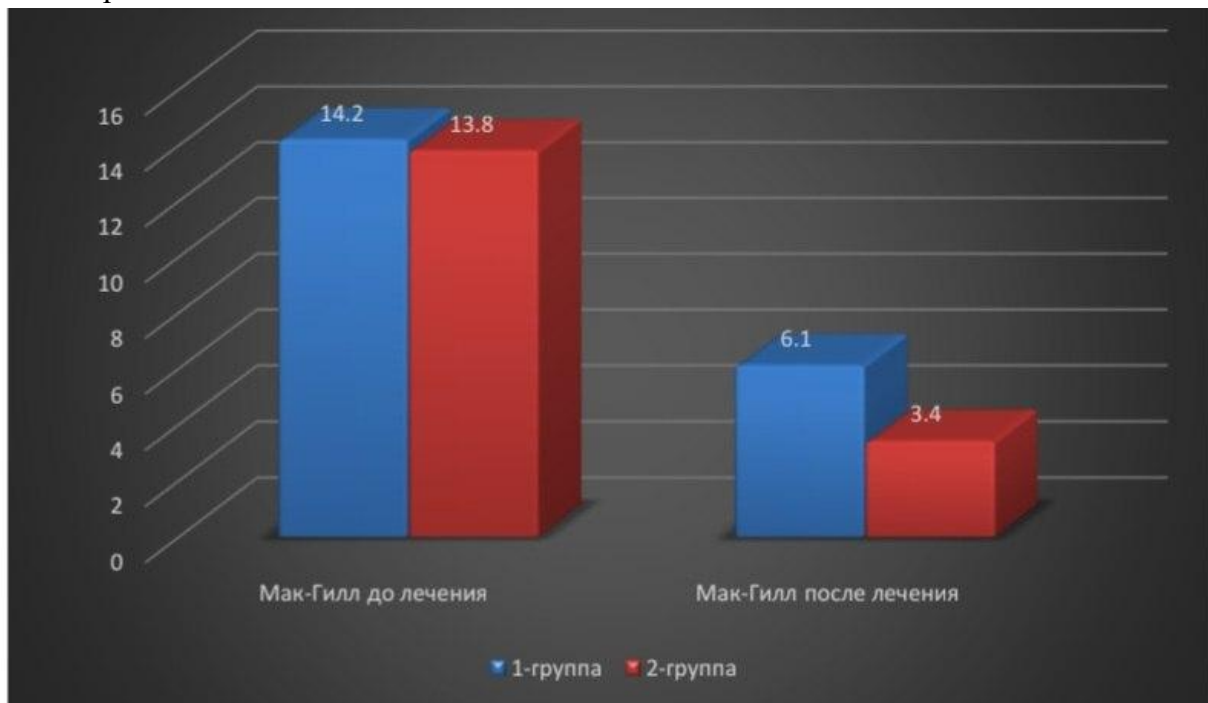
The following criteria were used to evaluate treatment results:

Significant improvement – cases of a good outcome, when anesthesia occurred in the affected area, no facial pain was present. The patient could speak and eat freely, feeling completely healthy.

Improvement – a group of patients in whom, after treatment, severe neuralgia attacks disappeared, but mild pain or paresthesia remained in the same facial area, not requiring treatment.

No change – a group of patients whose pain remained the same or only slightly improved.

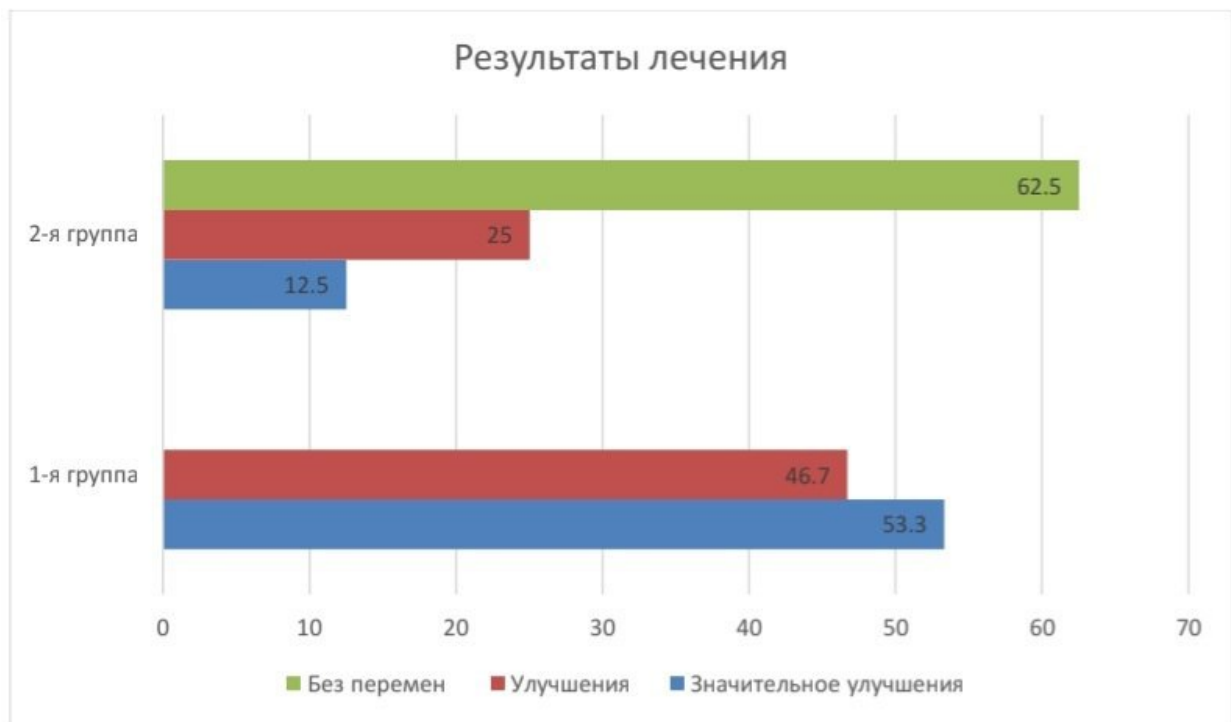
Results and discussion. During the treatment of patients with trigeminal neuralgia, it was found that many of them had a history of COVID-19 infection and had been treated according to standard protocols 3–6–9 months earlier.



До и после лечения по опроснику Мак-Гилл

During exacerbations of neuralgia symptoms, herpetic eruptions appeared along the course of the nerves in different stages. All patients were treated with the “Herpes-Stop” cream according to the prescribed regimen. In addition to antiviral therapy, immunomodulatory therapy with polyoxidonium was used.

Thanks to the combination with polyoxidonium, the “Herpes-Stop” cream increases the functional activity of the immune system and leads to rapid relief of pain symptoms and resolution of lesions in trigeminal neuralgia.



According to the treatment results, in patients who received only traditional therapy, the rash did not disappear within two weeks, and painful sensations persisted for a month.

Conclusion

Thus, a previous coronavirus infection is one of the most significant risk factors for reactivation of various types of viruses. Therefore, the use of the “Herpes-Stop” cream significantly increases the effectiveness of treatment by shortening the time of lesion resolution and reducing subjective discomfort in patients with trigeminal neuralgia. The immunomodulator polyoxidonium interacts well with many antiviral drugs, significantly enhancing their effects.

References

- 1.Sadikova Kh.K., Soliev Sh.M The effectiveness of the conservative method of treating trigeminal neuralgia with the drug “Nevrolon”.Biology and Medical Problems Journal, International Scientific Journal, No. 4(198), 2017, p.110.
- 2.Sadikova Kh.K., Soliev Sh.M., Mannonov Zh.Zh.The effectiveness of the conservative method of treating trigeminal neuralgia.Proceedings of the II International Scientific and Practical Conference “Topical Issues in Dentistry”, 2018, pp.123–125.
- 3.Wollina U., Karadağ A.S., Rowland-Payne C., Chiriac A., Lotti T.Cutaneous manifestations in COVID-19 patients: a review.Dermatol Ther. 2020; XXX:e13549. [Free article PMC] | [PubMed] | [Google Scholar].
- 4.B.V. Pinegin, A.V. Nekrasov, R.M. Khaitov.Polyoxidonium immunomodulator: Mechanism of action and aspects of clinical application.Institute of Immunology, Ministry of Health of the Russian Federation, Moscow, pp.44–47.

5.V.F. Sirazitdinova.Principles of treatment of herpetic infection against the background of anemia in children.Journal “Dermatovenereology and Aesthetic Medicine”, No.1/2015, Tashkent Pediatric Medical Institute, pp.34–36.

5.S.S. Arifov, A.A. Abdurashidov, Kh.T. Israilov.On the treatment of simple herpes. Journal “Dermatovenereology and Aesthetic Medicine”, No.2/2015,Tashkent Institute for Advanced Medical Training, Republican Specialized Scientific and Practical Medical Center of Dermatology and Venereology, Ministry of Health of the Republic of Uzbekistan, pp.59–61.

6.Koleneva Irina Evgenievna, Nalimova Tatyana Alexandrovna, Khozenok Nadezhda Alexandrovna.Method of treating herpetic lesions of vestibular, spiral, trigeminal, and knee ganglia.

7.Description of Invention for PatentApplication: 2004123911/14, dated 04.08.2004(24) Patent validity start date: 04.08.2004(45) Published: 27.01.2006, Bulletin No. 03Le Balc’h P., Pinceaux K., Pronier C., et al.Herpes simplex virus and cytomegalovirus reactivations among severe COVID-19 patients.Crit. Care, 2020; 24(1):530.

8.K. Katsikas Triantafyllidis, P. Giannos, IT Mian.Vaccines, 2021.R.A. Fathi, D.J. McMahon, K. Li, G.K. Chamberlin, M. Rosenbach, J.D. Lipoff, A.A. Tagi, S.R. Desai, F.L. French, J.B. Lim, J.B. Tver, J.G. Krusa, M.M. Fassett, L.P. Fox, H.L. Grinberg... (continues)

